

## Original Article

# The use of platelet rich plasma in the treatment of refractory Crohn's disease

Francesca Aparecida Ramos da Silva<sup>1</sup>, Bruno Lima Rodrigues<sup>1</sup>, Stephany Cares Huber<sup>1</sup>, Jose Luiz Rosenberis Cunha Júnior<sup>1</sup>, José Fabio Santos Duarte Lana<sup>1</sup>, Silmara Aparecida de Lima Montalvão<sup>1</sup>, Ângela Cristina Malheiros Luzo<sup>1</sup>, Maria Lourdes Setsuko Ayrizono<sup>2</sup>, Cláudio Saddy Rodrigues Coy<sup>2</sup>, Raquel Franco Leal<sup>2\*</sup>, Joyce Maria Annichino-Bizzacchi<sup>1\*</sup>

<sup>1</sup>Haemostasis Laboratory, Hematology Unit, Department of Internal Medicine, Faculty of Medical Sciences, University of Campinas (UNICAMP), Sao Paulo, Brazil; <sup>2</sup>Coloproctology Unit, Department of Surgery, Gastrocenter, Faculty of Medical Sciences, University of Campinas (UNICAMP), Sao Paulo, Brazil. \*Equal contributors.

Received April 13, 2016; Accepted August 19, 2016; Epub May 15, 2017; Published May 30, 2017

**Abstract:** Crohn's disease (CD) is a complex and multifactorial pathology. About 40% of patients cease to respond after available clinical therapy. Platelet rich plasma (PRP) is an alternative therapy widely used in the orthopedics and dentistry fields. Most recently, it has been studied in dermatological affections and autoimmune diseases. The aim was to evaluate the role of Platelet rich plasma (PRP) for refractory CD patients. Five patients diagnosed with ileocolic CD were selected. These patients were not taking any medication for at least two months and were resistant to biological therapy for at least one year. Growth factors, C-reactive protein, platelet and regulatory T cell frequency were measured at two different times: before treatment and after 12 injections of PRP (once a week). The activity of the disease was based on clinical and endoscopic indexes. The endoscopic score after PRP decreased in comparison to the baseline in four patients. Four patients had clinical remission, including the absence of joint pain. Two patients with perianal CD showed a decrease of discharge. No adverse effects such as allergic reactions were observed. Our findings suggest a short-term benefit of PRP for most refractory CD patients in this case series.

**Keywords:** Platelet rich plasma, Crohn's disease, inflammatory bowel disease

## Introduction

Crohn's disease (CD) is a chronic inflammatory bowel disease with unknown etiology, and it may affect any part of the gastrointestinal tract, especially the terminal ileum. CD is characterized by the formation of ulcers, fistulas and strictures, with periods of worsening and remission [1]. Immune factors are directly associated with CD: the patients present Th1/Th17 and Treg (regulatory T cell) disorders, which support the inflammatory symptoms [2]. The conventional clinical treatments comprise the use of immunosuppressive drugs and biological therapy. Besides the side effects, after a period of drug intake, 40% of the patients no longer respond to the treatment [3]. Therefore, the search for new effective treatments to induce a remission is needed.

Platelet-rich plasma (PRP) is a result of peripheral blood processing. It presents high concen-

tration of platelet [4]. This concentration is up to five times higher than the baseline platelet count (about 1 million platelet per microliter) [4, 5]. Recent studies are evaluating the functions of platelets more broadly, beyond hemostatic functions. Platelets participate in the inflammation process by releasing substances able to modulate inflammatory response by cell interactions to endothelial cells and leukocytes. PDGF, TGF- $\beta$ , CD40L and CD154 are found among the immunomodulatory factors [6]. TGF- $\beta$  is the main immunosuppressive molecule that influences Treg differentiation. This became evident in a study of immune thrombocytopenia, characterized by a decrease of Treg and TGF- $\beta$  that showed a functional and quantitative Treg restoration after being treated with therapies that increase the platelet count [7]. Due to the immunomodulatory characteristics, especially Treg differentiation by TGF- $\beta$ , PRP has the potential of being a therapeutic option for refractory CD. The objective of this study

## Platelet rich plasma for refractory Crohn's disease

was to evaluate the safety and results of the PRP for a series of patients with severe ileocolonic CD who did not respond to the biological therapy.

### Materials and methods

#### *Study subjects*

Patients with a confirmed endoscopic and histological diagnosis of CD from the Coloproctology Unit at the Gastrocenter of the University of Campinas (UNICAMP) were treated with PRP. Inclusion criteria were: age between 18 and 60 years, refractory to treatment, including biologic therapy, with no immune or anti-inflammatory medication for at least two months. Exclusion criteria were: previous bowel surgery, cancer, tobacco use, kidney or liver disease.

Five patients among 500, who were routinely followed-up in our Unit, were enrolled in this study. Two of them also presented perianal CD. All patients performed blood tests to analyze kidney and liver functions, hemogram, serology, erythrocyte sedimentation rate and C-reactive protein before (t1) and after 12 injections of PRP treatment (t2), i.e. one injection per week. Patients were subject to ileocolonoscopy before and after PRP treatment. Clinical and endoscopy scores were performed to evaluate disease activity. The following scores were used: Crohn's disease Activity Index (CDAI) [8], Crohn's Disease Endoscopic Index of Severity (CDEIS) [9]; and for perianal CD, Perianal Disease Activity Index (PDAI) [10].

This study was approved by the institutional ethics committee of the University of Campinas (May, 26th, 2014, Brazil). A written informed consent was obtained from all patients.

#### *PRP preparation and administration*

For each patient, three 8.5 mL ACD tubes, one 4 mL EDTA tube and another one without anticoagulant of peripheral blood were collected (BD Vacutainer). PRP preparation was performed according to the Amable methodology [11]: all ACD tubes were double centrifuged, the first spin at 300 g for 5 minutes, and the second spin at 700 g for 17 minutes. At the end of the second spin, the top layer plasma (80% of the total volume) was characterized as platelet

poor plasma (PPP) and the lower layer (20% of the total volume), as PRP. The platelets were counted in the baseline and in the PRP samples by the Siemens Advia120 and Advia2120i haematology analysers. The tube without anticoagulant was used for autologous serum. After a centrifugation at 1258 g for 15 minutes, 0.5 mL was taken and then added to the PRP syringe right before the injection to activate the platelets. The entire procedure was carried out in a laminar flow cabinet and all materials were sterile.

All patients were treated with subcutaneous per umbilical injections. A volume of 2.5 mL were injected each week up to 12 injections. In case of any adverse event, the following injection was postponed until it was over.

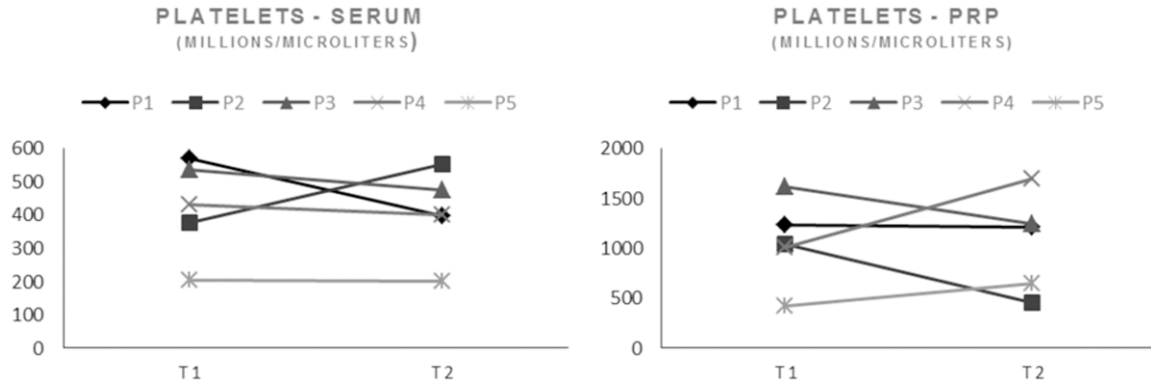
#### *Growth factor dosage*

The growth factors we evaluated were: Platelet-derived growth factor AA (PDGF-AA), Epidermal growth factor (EGF), Vascular endothelial growth factor (VEGF), Transforming growth factor beta (TGF- $\beta$ ) and Platelet factor 4 (PF4). These growth factors were determined by the Luminex technique (Millipore, USA), a multiplex methodology capable of detecting the growth factors included in this study simultaneously, thus providing better technical reproducibility and more accurate results. The method consists of magnetic beads coated with monoclonal antibodies specific to the human protein to be determined. To conduct this technique, the activated samples were incubated in a water bath at 37°C for one hour. The samples were then treated with 3 cycles of nitrogen to dissolve the clot and the protocol for Luminex was initiated. Growth factors were evaluated at the baseline and after 12 weeks of treatment.

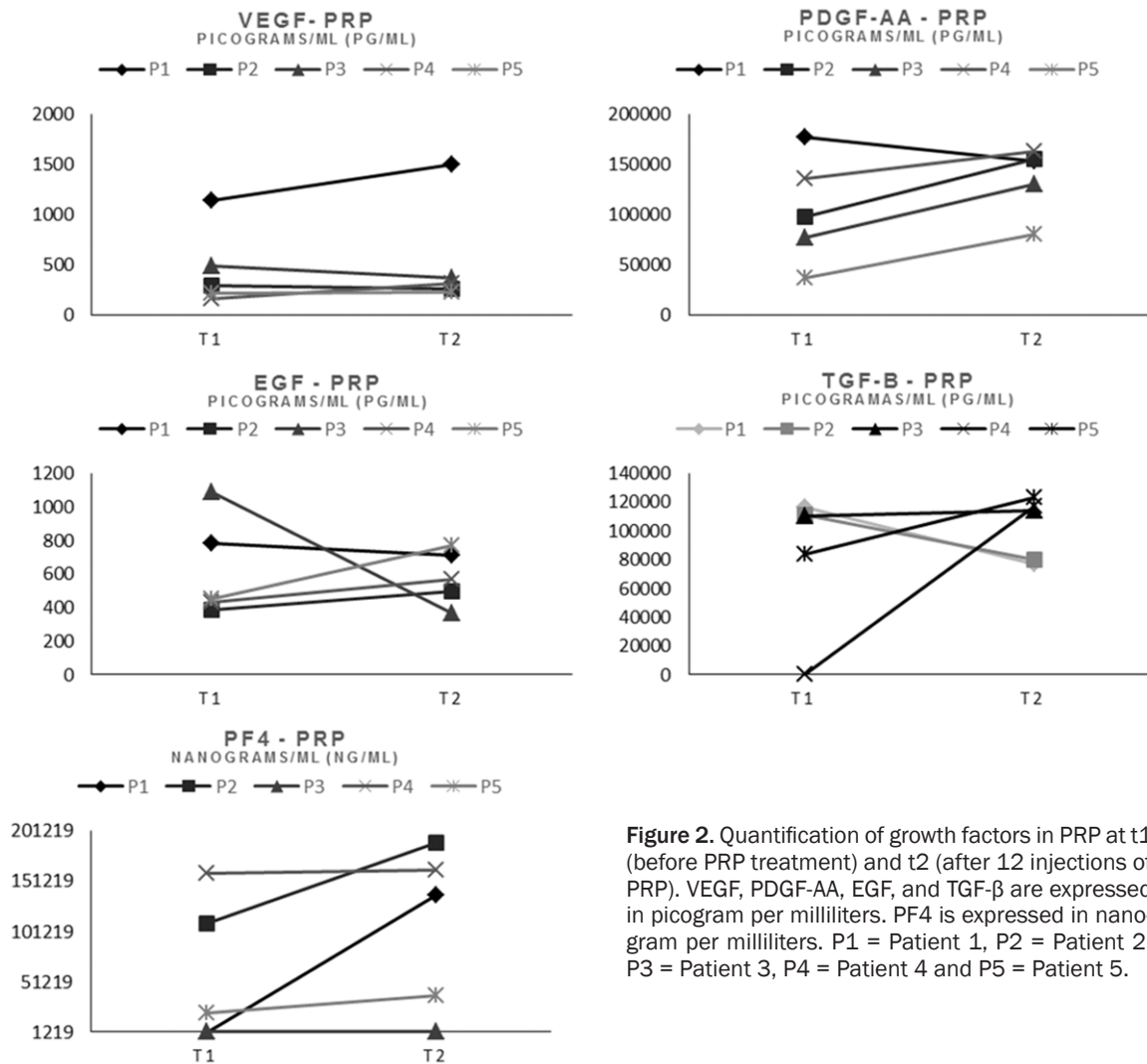
#### *Flow cytometry*

Samples of peripheral blood were collected into a tube containing the anticoagulant heparin. The process of obtaining and quantifying cellular frequency followed the manufacturer's instructions protocol (BD Biosciense, USA). The antibodies were used for Treg CD45 FITC, CD4 PerCP, CD25PE APC and anti-FoxP3. The CD45 FITC, CD4 PerCP and CD25PE antibody were added in the first step of treating samples as APC anti-FoxP3 was added after treatment of

## Platelet rich plasma for refractory Crohn's disease



**Figure 1.** Platelet count in serum and after preparation of PRP, at t1 (before PRP treatment) and t2 (after 12 injections of PRP). Platelets are expressed in million per microliters. P1 = Patient 1, P2 = Patient 2, P3 = Patient 3, P4 = Patient 4 and P5 = Patient 5.

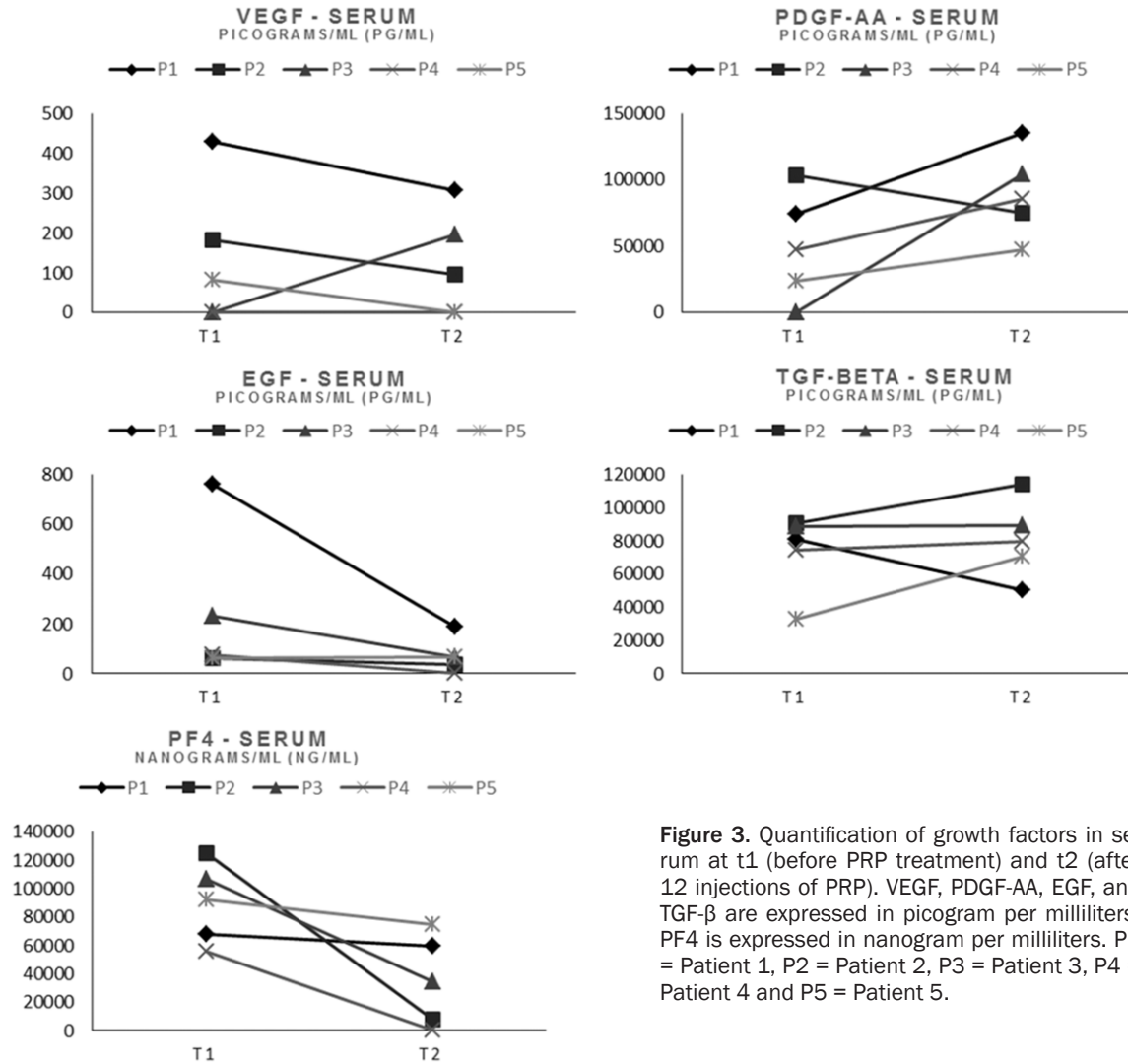


**Figure 2.** Quantification of growth factors in PRP at t1 (before PRP treatment) and t2 (after 12 injections of PRP). VEGF, PDGF-AA, EGF, and TGF- $\beta$  are expressed in picogram per milliliters. PF4 is expressed in nanogram per milliliters. P1 = Patient 1, P2 = Patient 2, P3 = Patient 3, P4 = Patient 4 and P5 = Patient 5.

the sample with Fix/Perm (Bioscience BD, USA). The content was suspended in PBS and

forwarded to reading flow cytometer (BD FACSCanto™, USA).

## Platelet rich plasma for refractory Crohn's disease



**Figure 3.** Quantification of growth factors in serum at t1 (before PRP treatment) and t2 (after 12 injections of PRP). VEGF, PDGF-AA, EGF, and TGF- $\beta$  are expressed in picogram per milliliters. PF4 is expressed in nanogram per milliliters. P1 = Patient 1, P2 = Patient 2, P3 = Patient 3, P4 = Patient 4 and P5 = Patient 5.

### Statistical analysis

Descriptive statistical analysis was performed before and after treatment. Numerical variables were expressed by mean with the maximum and minimum value, and categorical variables were expressed by absolute frequency.

### Results

Five patients participated in the study [mean age, 32.2 (range, 27-42) years; 2 male; 3 female]. Blood sample analyses were performed at two moments: time 1 (t1) before PRP treatment and time 2 (t2) after 12 injections of this therapy. PRP analysis was performed at the same time.

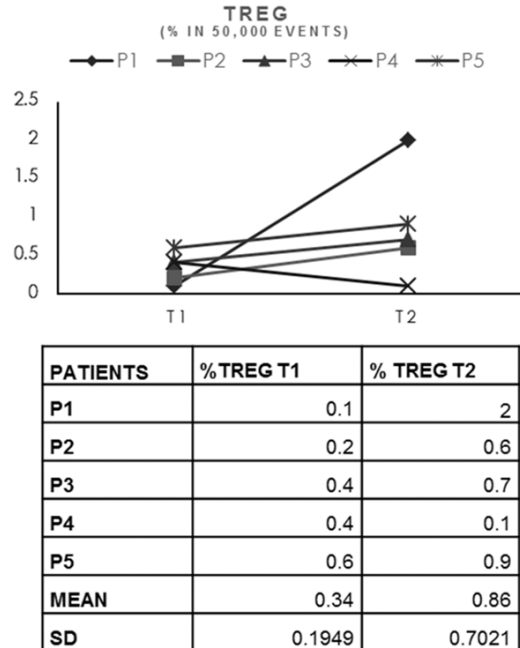
### Platelet quantification in serum samples and PRP

The mean of serum platelet count from all patients at t1 was  $423.4 \times 10^6/\mu\text{L}$  (range 205-571), and at t2 it was  $404.0 \times 10^6/\mu\text{L}$  (range 200-551). The mean of platelet count in PRP at t1 was  $1,064.4 \times 10^6/\mu\text{L}$  (range 420-1,620), and at t2 it was  $1,048.6 \times 10^6/\mu\text{L}$  (range 646-1,695). These results are shown in the **Figure 1**.

### Growth factor dosage in PRP and serum samples

Growth factors were dosed in serum samples and in PRP in order to assess individual differences between t1 and t2 samples. Most of

## Platelet rich plasma for refractory Crohn's disease



**Figure 4.** Treg cell frequency in peripheral blood at t1 (before PRP treatment) and t2 (after 12 injections of PRP). Results are shown in percentage in 50,000 events. P1 = Patient 1, P2 = Patient 2, P3 = Patient 3, P4 = Patient 4 and P5 = Patient 5.

growth factors maintained the same range of values in t1 and t2, observing each patient separately (**Figures 2 and 3**). Only one patient (Patient 4) presented a higher increase of TGF- $\beta$  comparing t1 and t2 in the PRP, but not in the serum. Also, Patient 1 had increased levels of PF4 in t2, compared to t1 in the PRP, but not in the serum.

### Treg cell frequency

Most of the patients showed no improvement in Treg cell frequency in peripheral blood. The most expressed value was from patient 1, whose cell frequency was 0.1% of Treg in 50.000 cells (t1) and 2% (t2). The cell frequencies of patient 2 was 0.2% (t1) and 0.6% (t2); patient 3, 0.4% (t1) and 0.7% (t2); patient 4, 0.4% (t1) and 0.1% (t2); and patient 5, 0.6% (t1) to 0.9% (t2). (**Figure 4**) The mean number of Treg cell frequency at t1 was 0.34% (range 0.1-0.6), and at t2 it was 0.86% (range 0.1-2).

### Evaluation of clinical and endoscopic response

Patients 1, 3, 4 and 5 showed an improvement in both clinical and endoscopic response.

Patient 2 showed a little clinical improvement and no endoscopic improvement. Regarding PDAI, patients 1 and 2 showed an improvement after treatment. The mean CDAI value at t1 was 294.8 (range 215.4-302.2), and at t2 it was 187.1 (range 98-262.6); mean CDEIS at t1 was 15.1 (range 11-19.7), and t2 it was 10.7 (range 6.3-16.2); and mean PDAI at t1 was 7.5 (range 7-8), and t2 it was 5 (range 4-6). The mean CRP value at t1 was 5.96 mg/dl (range 0.27-17.64), and at t2 it was 2.48 mg/dl (range 0.61-3.63) (**Figures 5 and 6**).

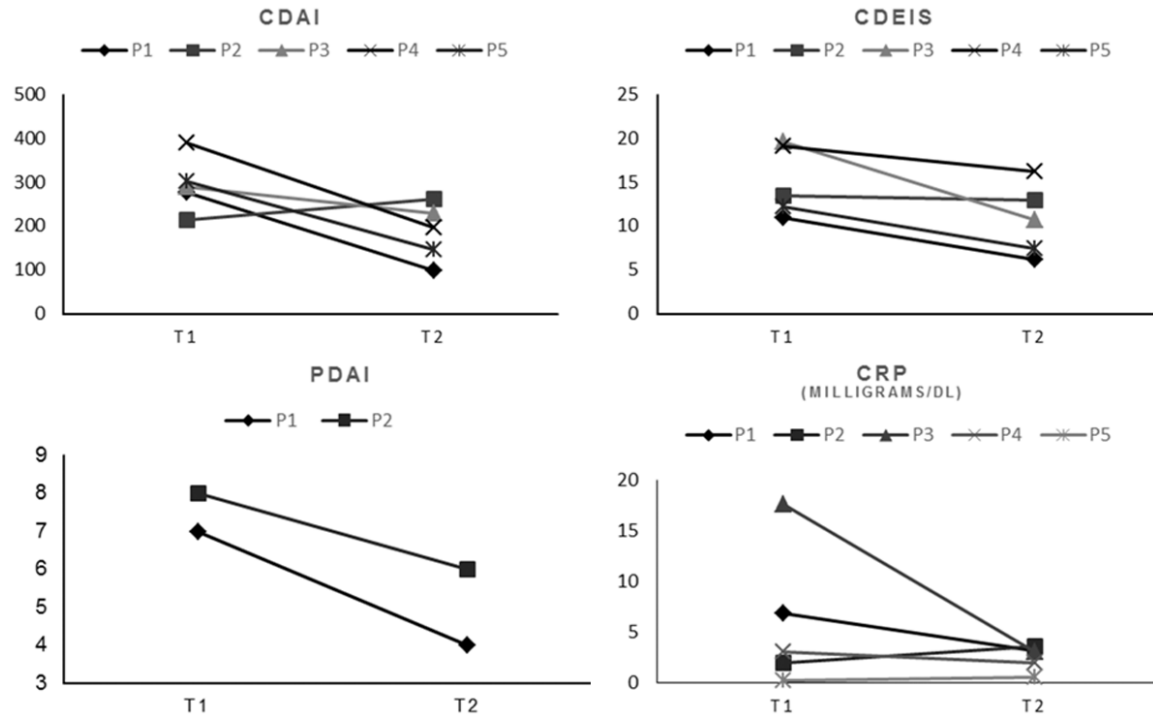
### Cases report

**Patient 1:** Female, twenty-seven years old, has had CD for ten years, with involvement of the anal canal, rectum and left colon. She had previously taken corticosteroids, azathioprine and adalimumab. She experienced weight loss, joint pain, frequent abdominal cramps, five bloody and mucous bowels movement per day, and the large skin tags in the perianal region. Due to anemia (7 mg/dL of hemoglobin), before the treatment with PRP, the patient received three intravenous infusions of 500 mg of iron III diluted in 250 mL of saline 0.9% for three weeks. After this treatment, the hemoglobin increased to 13 mg/dL and it kept stable throughout the 3 months of treatment with PRP. The patient reported a decrease of abdominal cramps both in intensity and in frequency. There was no difference in bowel movement per day, but the feces consistency became pasty. CDAI decreased from 277 to 98 points. The ileocolonoscopy examination after 3 months of treatment (12 injections) showed a decrease in the number of ulcers and reduced intestinal involvement. CDEIS decreased from 11 to 6.25 points; and PDAI decreased from 7 to 4 points (**Figures 5 and 6**).

The patient gained 7 Kg during the treatment. Throughout this period, the patient had biweekly nutrition monitoring, maintaining oral nutritional supplementation. After the end of the protocol, she began biological therapy (infliximab) and had follow-up of 6 months. Due to incomplete endoscopic response and severe clinical activity of the disease, in spite of the use of Infliximab, she underwent a total colectomy with good evolution.

**Patient 2:** Female, 29 years old, has had CD for seven years with involvement of the left colon, sigmoid colon, rectum and perianal region. She

## Platelet rich plasma for refractory Crohn's disease



**Figure 5.** Evaluation of inflammatory activity before (t1) and after treatment with PRP (t2). CDAI (Crohn's disease Activity Index), CDEIS (Crohn's Disease Endoscopic Index of Severity), PDAI (Perianal Disease Activity Index), and CPR (C-reactive protein) were evaluated. P1 = Patient 1, P2 = Patient 2, P3 = Patient 3, P4 = Patient 4 and P5 = Patient 5.

had previously taken corticosteroids, azathioprine and adalimumab. She had three perianal fistulas with seton. The patient also reported intense abdominal cramps, seven bloody and mucous bowel movement per day with liquid feces. After thirty days of treatment with PRP, the patient reported absence of bloody and mucous evacuation with no improvement of either the abdominal cramps or the number of bowel movements per day. After forty-five days (6 injections) of treatment, there was an increase in abdominal cramps, both in intensity and in frequency. There was a clinical worsening after twelve injections of PRP, related to an increase of the CDAI score from 215.4 to 262.6 points. There was no relevant improvement in endoscopic scores. CDEIS decreased from 13.5 to 12.9 points; and PDAI decreased from 8 to 6 points (**Figures 5 and 6**).

The perianal setons were kept, and there was a slight decrease in the PDAI score. The patient did not gain weight, despite nutrition follow-up. Due to absence of clinical and endoscopic improvement after 3 months (12 injections) of PRP, the patient started receiving Infliximab, which she had never taken before. The patient

had follow-up for six months after the end of the protocol. She showed clinical improvement at the beginning of the biological therapy. However, due to lack of response and fibrostenosis of ileocecal valve, she underwent an ileocolic resection.

*Patient 3: Female, thirty-one years old, presented CD for eleven years, with involvement of right and sigmoid colon, and rectum. Before the PRP treatment, she reported intense abdominal and joint pain with seven bloody and mucous bowel movements per day. After the third injection of PRP, she reported absence of joint pain, which did not return until the present moment. There was a noticeable improvement of symptoms after the fourth injection. The patient had several complications throughout the treatment, such as urinary tract infections, sinus infections and food intoxication. Due to these complications, PRP had to be interrupted for two weeks while she was recovering. Both clinical and endoscopic scores were decreased after twelve injections. CDAI decreased from 288.6 to 230.5 points and CDEIS from 19.2 to 10.7 points (**Figures 5 and 6**).*



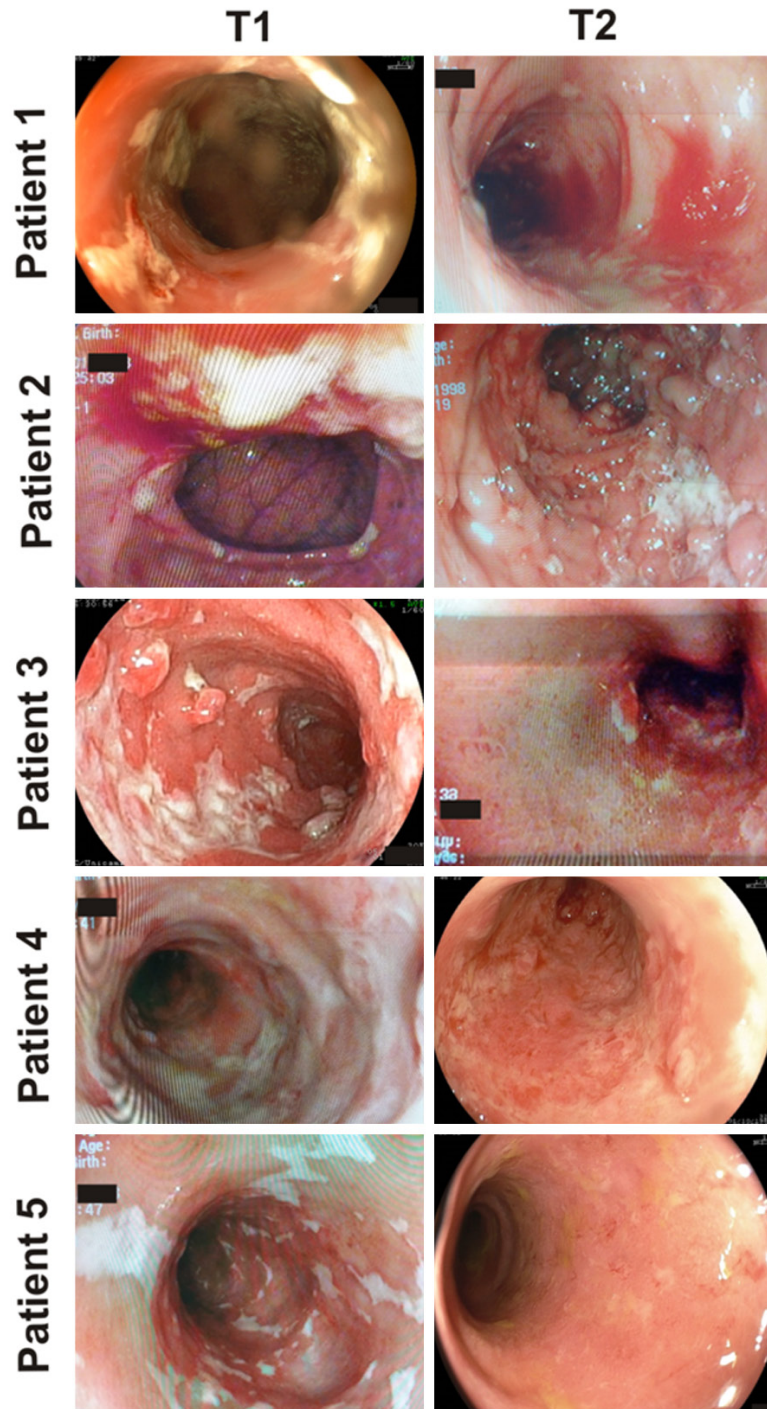


Figure 6. Endoscopic features before (t1) and after treatment with PRP (t2).

She gained 2.5 Kg during the treatment, and experienced increased appetite and felt more willingness to perform daily tasks. The bowel movements per day remained unchanged (7 times per day), but with a pasty consistency. The patient was followed-up for 9 months, and she is asymptomatic.

*Patient 4:* Male, thirty-two years old, presented CD for five years, with involvement of the entire colon and rectum. He had previously taken azathioprine for four years and azathioprine with biological therapy for one year. Before the treatment with PRP, he reported intense abdominal cramps, liquid-bloody-mucous feces, 9 bowel movements per day and gradual weight loss over the last five years. In the second week of PRP treatment, the patient reported absence of abdominal cramps and willingness to do daily tasks. After the fifth week, the patient had food intoxication, which led to an increase of bowel movements and abdominal cramps for 1 week. After twelve injections (3 months of therapy), he no longer reported abdominal cramps, blood and mucous in the feces. Bowel movements decreased to six times per day with a pasty-to-semi solid consistency and he gained 5 Kg during the treatment. Although there was no significant improvement in the endoscopic scores, the clinical score decreased after twelve injections of PRP. CDAI decreased from 391 to 198 points and CDEIS from 19.2 to 16.2 points (Figures 5 and 6).

Ileocolonoscopy at t2 revealed several alterations in the mucosa, suggestive of adenoma, which was confirmed by anatomopathological analysis (adenoma with moderate grade of dysplasia). For this reason, he underwent a total colectomy, with satisfactory evolution.

confirmed by anatomopathological analysis (adenoma with moderate grade of dysplasia). For this reason, he underwent a total colectomy, with satisfactory evolution.

*Patient 5:* Male, forty-two years old, presented CD for nine years, with involvement of the entire

colon and rectum. He had previously taken immunosuppressive drugs and biological therapy for one year. Before the treatment with PRP, the patient reported mild abdominal cramps, fifteen bowel movements per day with liquid feces with blood and mucous. After four injections of PRP, he reported clinical improvement. After twelve injections (3 months), the patient reported a decrease in bowel movements to five times per day, with semi-pasty consistency without abdominal cramps. There was a decrease in both clinical and endoscopic scores. CDAI decreased from 302.2 to 146.4 points and CDEIS from 12.3 to 7.4 points (Figures 5 and 6).

The patient was followed-up for six months after the end of protocol, and due to the remaining endoscopic lesions, he started Infliximab, and is asymptomatic.

The median time of patients follow-up was 6 (1-9) months. Two patients are asymptomatic. Three patients needed surgery, one due to moderate grade dysplasia, and the others due to remaining endoscopic lesions and symptomatic disease.

### Discussion

CD is a complex and multifactorial disease, and may affect the entire gastrointestinal system. The pathophysiology of CD is not well understood and there are several hypotheses of its etiology: defects in the barrier of the intestinal mucosa, dysbiosis, persistent pathogen infection and immune deregulation. Interaction among many factors is the most accepted hypothesis, such as genetic, environmental, presence of microorganisms and intestinal epithelium. These associations between genetic factors, alterations of the innate and adaptive immune response, environmental factors, bacterial flora, diet and hygiene and sanitary conditions, may be responsible for triggering or maintaining intestinal inflammation [12]. Patients with CD have low tolerance to commensal bacteria antigens, and especially a reduced ability to defend the mucosa against pathogens [13]. Tolerance can be measured essentially by intestinal epithelial cells (IEC), regulatory T cells (Treg cells), B lymphocytes, and dendritic cells, which release IL-10, IFN- $\alpha/\beta$  and TGF- $\beta$  [14]. These aspects may be responsible for the differences in clinical manifestations and

response to treatments in each patient, requiring a tailored approach with several medications.

Pharmacological treatment for CD is based on the use of aminosalicylates, corticosteroids, immunosuppressants and biological therapy. Thus far, about 50-60% maintains clinical remission with this approach. Biological therapy, anti-tumor necrosis factor  $\alpha$  (anti-TNF- $\alpha$ ) was approved in 1998 for CD in USA. The main drugs of this class are infliximab and adalimumab. The advent of biological therapy was certainly a breakthrough in the clinical management of CD. However, up to 40% of patients cease to respond in long-term follow-up [3, 15]. There are currently several drug classes being developed for treatment of CD, such as other biological as well as cell therapies.

The platelet-rich plasma (PRP) is a product derived from autologous blood processing [11]. This product has a high concentration of platelets and is diluted in small volumes of plasma [4]. The processing of this product is very diverse, and the time of centrifugation is not established to common use in all clinical injections [16]. Studies of PRP in other clinical situations have proven effective in treating osteoarthritis and chronic skin ulcers [17-20]. Other studies are being conducted to confirm the efficacy of PRP in inflammatory and degenerative musculoskeletal injuries. Lippross et al. [21] evaluated PRP in animal models of rheumatoid arthritis with severe inflammation. Although there had been only intra-articular injections, there was a systemic effect on concentrations of inflammatory markers, reducing IL-6, VEGF, IGF-1 and IL-1 [21]. The protein analysis of PRP in that study demonstrated an unusual amount of secretory proteins associated with the modulation of the inflammation. Göttgens et al. [22] used PRP local injection during the mucosa advancement flap procedure for high perianal fistula of CD patients. However, there was no CD activity at that moment of the surgery, and PRP was used to improve outcomes of the perineal surgery, not for immunomodulation of the disease, as proposed here. Platelets have a key role in PRP due to the  $\alpha$ -granules and dense granules. Within the  $\alpha$ -granules growth factors, the most important are: growth factor platelet-derived isomers (PDGF-AA, PDGF-BB and PDGF-AB), transforming growth factor (TGF- $\beta$ 1



and TGF- $\beta$ 2), growth factor derived from the endothelium (VEGF), and epidermal growth factor (EGF) [5]. The platelets and the released growth factors are essential for regulating cellular events which occur after tissue damage [21].

In the present study, we evaluated the use of PRP in the treatment of CD patient refractory to biological therapy. The disease's activity was assessed by clinical and endoscopic indexes. We underscore that selected patients had a severe form of the disease, and due to the non-existence of any other therapy, we recruited them to participate in this protocol. Despite the decrease of endoscopic scores compared to the baseline time, no complete endoscopic remission was achieved. However, most of the patients had clinical response (decrease in CDAI), including the absence of joint pain. The two patients with perianal CD kept their setons with decreased secretion. No adverse events such as allergic reactions were observed, although one patient developed colonic adenomas throughout the treatment. One advantage that we observed was that the characteristic high levels of platelet in active CD patients lead us to collect a smaller amount of peripheral blood each week, when compared to patients with other diseases. Another advantage of PRP is its cost, which is very low. We just needed a centrifugation protocol as described, and the patients had to burden the costs to come to the outpatient clinic every week.

Regarding the endoscopic and clinical response, it did not correlate with the levels of TGF- $\beta$  and there may be, therefore, other immunoregulatory factors in the PRP that can be associated to this response which should be investigated. The main hindrance to understanding the action mechanisms of this type of therapy is the immense amount of factors present in PRP.

In summary, despite the limited number of patients included in this study, we conclude that there was a short-term benefit of PRP for most patients in this case series with CD refractory to biological therapy. PRP may offer a therapy option for this group of patients who do not respond to anti-TNF agents. However, follow-up time is short and a large prospective study to confirm this data is still needed.

### Acknowledgements

We thank CAPES (Brazilian Federal Agency for Support and Evaluation of Graduate Education within the Ministry of Education of Brazil) for financial support. We thank D. S. P. Costa and G.J.N. Ferraz for technical assistance and Prof. T. G. Torriani for linguistic revision.

### Disclosure of conflict of interest

None.

**Address correspondence to:** Dr. Raquel F Leal, Coloproctology Unit, Department of Surgery, Gastrocenter, Faculty of Medical Sciences, University of Campinas (UNICAMP), João Lopes Vieira Street, 108, apto 61, Villa Bella Dom Pedro, CEP 13087-734, Campinas, Sao Paulo, Brazil. Tel: +55-19-991375374; Fax: +55-19-33059982; E-mail: raf-ranco.unicamp@gmail.com

### References

- [1] Baumgart DC, Sandborn WJ. Inflammatory bowel disease: clinical aspects and established and evolving therapies. *Lancet* 2007; 12: 1641-57.
- [2] Collison LW, Chaturvedi V, Henderson AL, Giacomini PR, Guy C, Bankoti J, Finkelstein D, Forbes K, Workman CJ, Brown SA, Rehg JE, Jones ML, Ni HT, Artis D, Turk MJ, Vignali DA. IL-35-mediated induction of a potent regulatory T cell population. *Nat Immunol* 2010; 11: 1093-101.
- [3] Schreiber S, Colombel JF, Bloomfield R, Nikolaus S, Schölmerich J, Panés J, Sandborn WJ; PRECISE 2 Study Investigator. Increased response and remission rates in short-duration Crohn's disease with subcutaneous certolizumab pegol: an analysis of PRECISE 2 randomized maintenance trial data. *Am J Gastroenterol* 2010; 105: 1574-82.
- [4] Marx RE. Platelet-rich plasma: evidence to support its use. *J Oral Maxillofac Surg* 2004; 62: 489-486.
- [5] Eppley B, Pietrzak WS, Blanton M. Platelet-rich plasma: a review of biology and applications in plastic surgery. *Plast Reconstr Surg* 2006; 118: 147e-159e.
- [6] Cognasse F, Bousoulade F, Chavarin P, Anderson R. Release of potential immunomodulatory factors during platelet store. *Transfusion* 2006; 46: 1184-1189.
- [7] Semple JW, Italiano JE Jr, Freedman J. Platelets and the immune continuum. *Nat Rev Immunol* 2011; 11: 264-274.

## Platelet rich plasma for refractory Crohn's disease

- [8] Best WR, Becktel JM, Singleton JW, Kern F Jr. Development of a Crohn's disease activity index: National Cooperative Crohn's Disease Study. *Gastroenterology* 1976; 70: 439-44.
- [9] Mary JY, Modigliani R. Development and validation of an endoscopic index of the severity for Crohn's disease: a prospective multicenter study. *Groupe d'Etudes Therapeutiques des Affections Inflammatoires du Tube Digestif (GETAID). Gut* 1989; 30: 983-9.
- [10] Irvine EJ. Usual therapy improves perianal Crohn's disease as measured by a new disease activity index. *McMaster IBD Study Group. J Clin Gastroenterol* 1995; 20: 27-32.
- [11] Amable PR, Carias RBV, Teixeira MVT, da Cruz Pacheco I, Corrêa do Amaral RJ, Granjeiro JM, Borojevic R. Platelet-rich plasma preparation for regenerative medicine: optimization and quantification of cytokines and growth factors. *Stem Cell Res Ther* 2013; 4: 1-13.
- [12] Schirbel A, Fiocchi C. Inflammatory Bowel disease: established and evolving considerations on its etiopathogenesis and therapy. *J Dig Dis* 2010; 11: 266-76.
- [13] Torres MI, Rios A. Current View of immunopathogenesis in inflammatory bowel disease and implications of therapy. *World J Gastroenterol* 2008; 7: 1972-80.
- [14] Sartor RB. Mechanisms of disease: pathogenesis of Crohn's disease and ulcerative colitis. *Nat Clin Pract Gastroenterol Hepatol* 2006; 3: 390-407.
- [15] Maharshak N, Plevy SE. A Crohn's disease patient who does not respond to infliximab: what is next? *Clin Gastroenterol Hepatol* 2011; 9: 1033-8.
- [16] Liao HT, Marra KG, Rubin JP. Application of platelet-rich plasma and platelet-rich fibrin in fat grafting: basic science and literature review. *Tissue Eng Part B Rev* 2014; 20: 267-76.
- [17] Patel S, Dhillon MS, Aggarwal S, Marwaha N, Jain A. Treatment with platelet-rich plasma is more effective than placebo for knee osteoarthritis: a prospective, double-blind, randomized trial. *Am J Sports Med* 2013; 41: 356-364.
- [18] Filardo G, Kon E, Di Martino A, Di Matteo B, Merli ML, Cenacchi A, Fornasari PM, Marcacci M. Platelet-rich plasma vs hyaluronic acid to treat knee degenerative pathology: study design and preliminary results of a randomized controlled trial. *BMC Musculoskelet Disord* 2012; 13: 229.
- [19] Torrero JI, Aroles F, Ferrer DJ. Treatment of knee chondropathy with platelet rich plasma. Preliminary results at 6 months of follow-up with only one injection. *Biol Regul Homeost Agents* 2012; 26: 71S-78S.
- [20] Sarvajnamurthy S, Suryanarayan S, Budamakuntala L, Suresh DH. Autologous platelet rich plasma in chronic venous ulcers: study of 17 cases. *J Cutan Aesthet Surg* 2013; 6: 97-99.
- [21] Lippross S, Moeller B, Haas H, Tohidnezhad M, Steubesand N, Wruck CJ, Kurz B, Seekamp A, Pufe T, Varoga D. Intra-articular injection of platelet-rich plasma reduces inflammation in a pig model of rheumatoid arthritis of the knee joint. *Arthritis Rheum* 2011; 63: 3344-53.
- [22] Göttgens KW, Smeets RR, Stassen LP, Beets GL, Pierik M, Breukink SO. Treatment of Crohn's disease-related high perianal fistulas combining the mucosa advancement flap with platelet-rich plasma: a pilot study. *Tech Coloproctol* 2015; 19: 455-9.