BI-RADS® ULTRASSONOGRAFIA

Paula Moraes

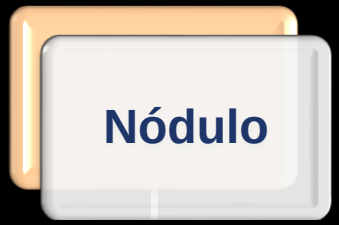

Lesão que ocupa espaço, bordas externas convexas

Tridimensional: Vista em diferentes incidências

(angulação do transdutor)

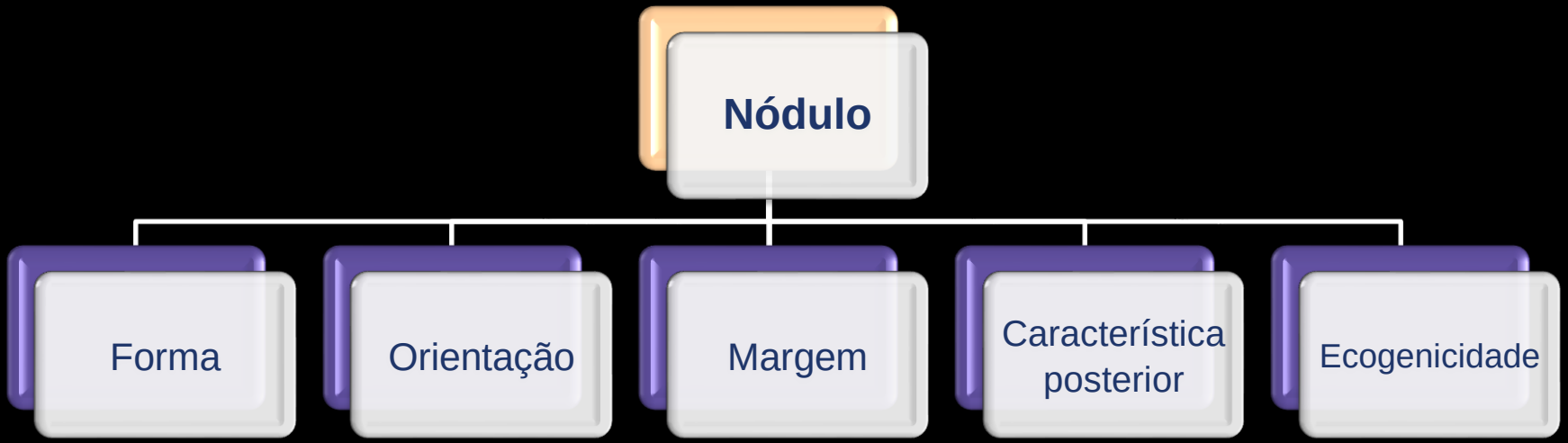
Nódulo
Forma
Orientação
Margem
Característica posterior
Ecogenicidade

Nódulo

- Forma
- Orientação
- Margem
- Característica posterior
- Ecogenicidade

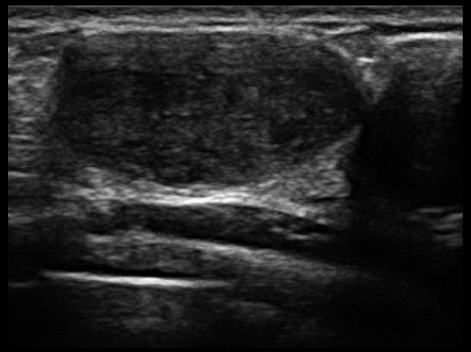

oval (inclui até 3 lobulações)

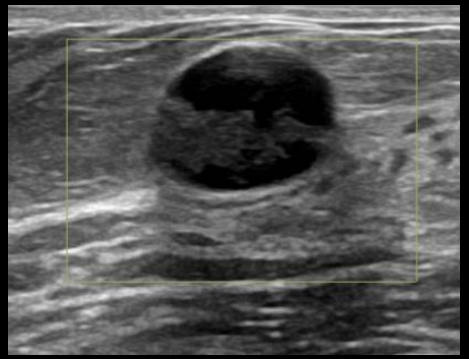

redondo

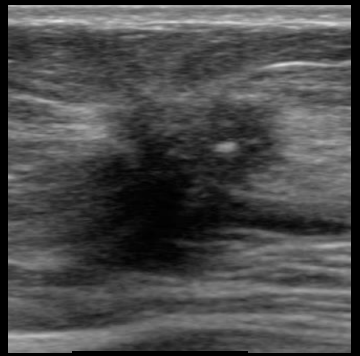

irregular

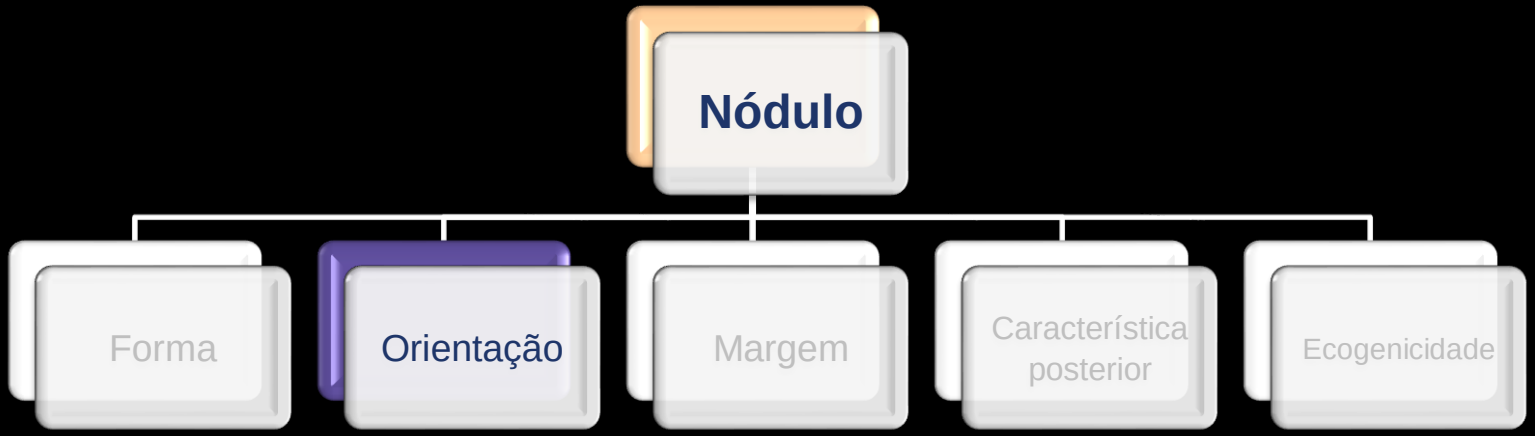

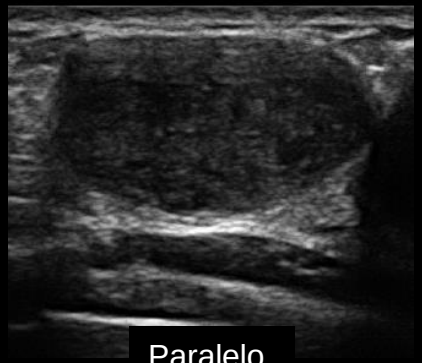

Maior eixo do nódulo em relação a pele

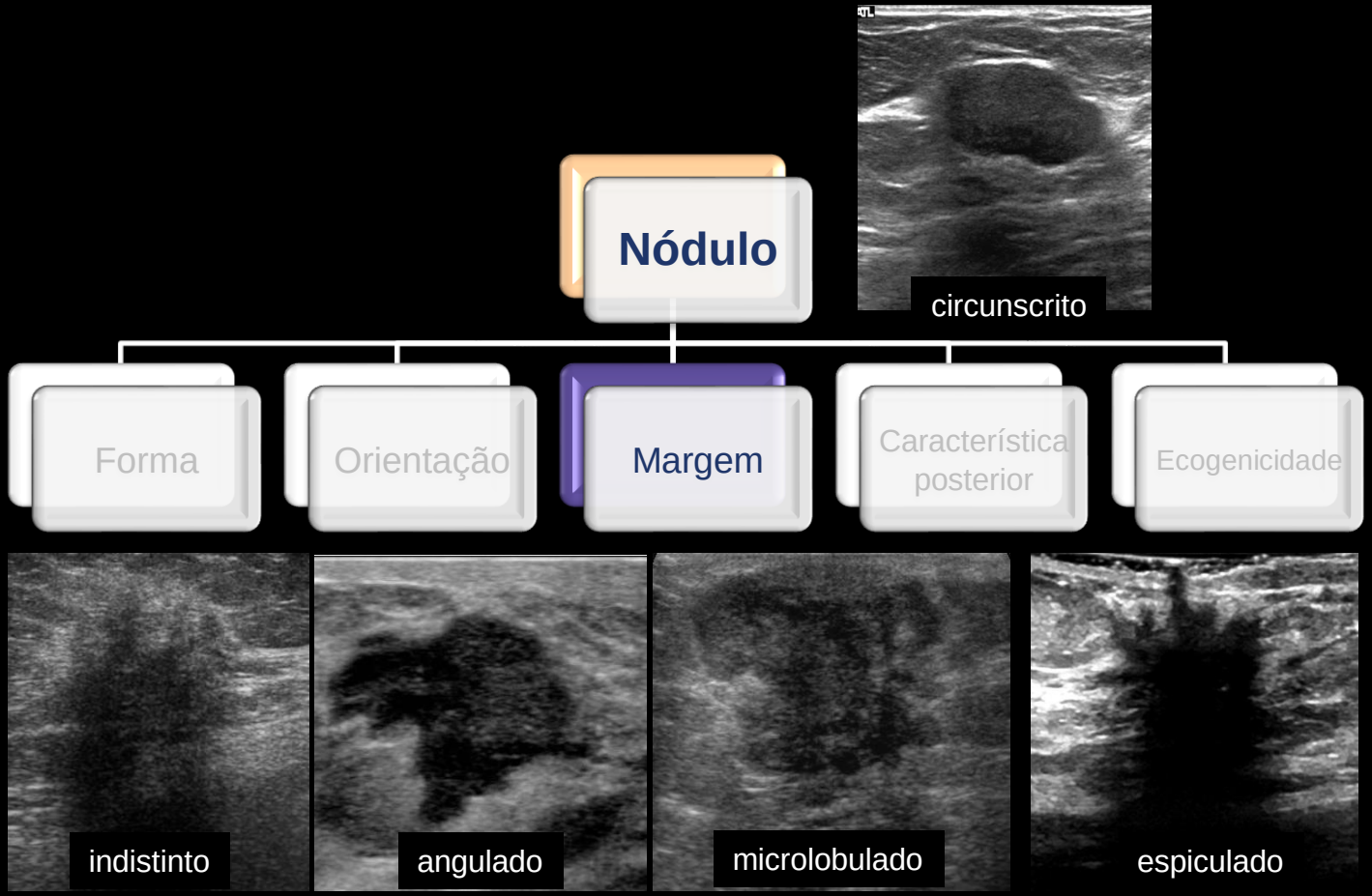
Nódulo
circunscrito
circunscritas
Forma
Orientação
Margem
Característica posterior
Ecogenicidade
indistinto
angulado
microlobulado
espiculado
Não circunscritas

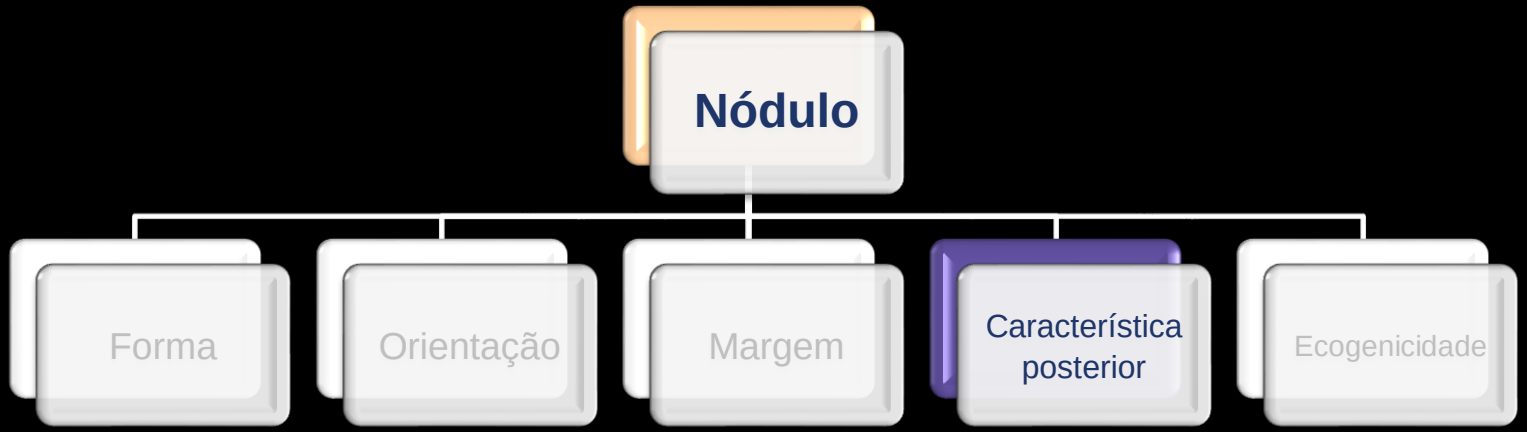

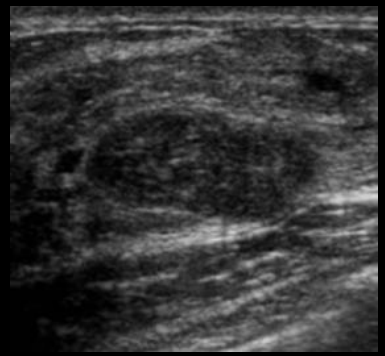

sem efeito posterior

sombra

reforço

padrão misto

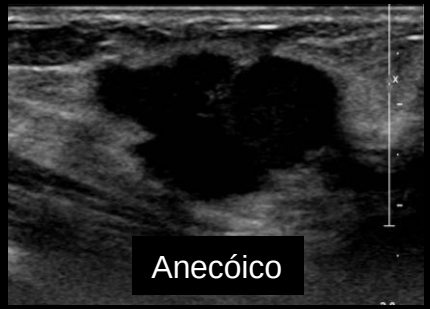

Nódulo

- Forma
- Orientação
- Margem
- Característica posterior
- Ecogenicidade

Isoecóico

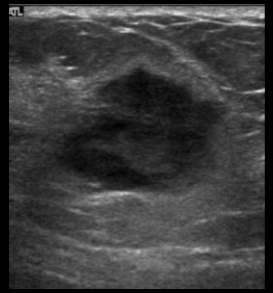

hipoecóico

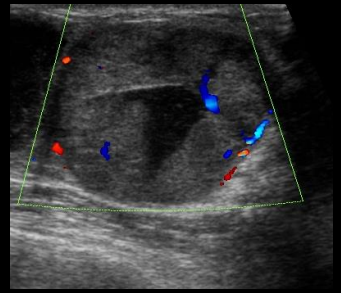

Complexo sólido-cístico

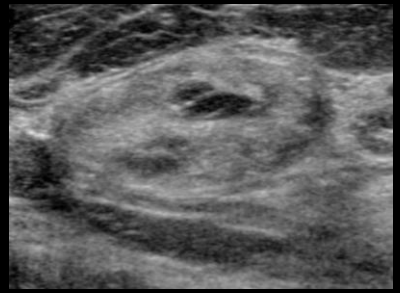

heterogêneo

Forma	Margem	Orientação



Linfonodomegalia

Invasão pele

Invasão CAP

Extensão ductal

Halo ecogênico periférico*

(echogenic rind)

Halo ecogênico periférico: faixa ecogênica espessa circundando parte ou a totalidade da lesão

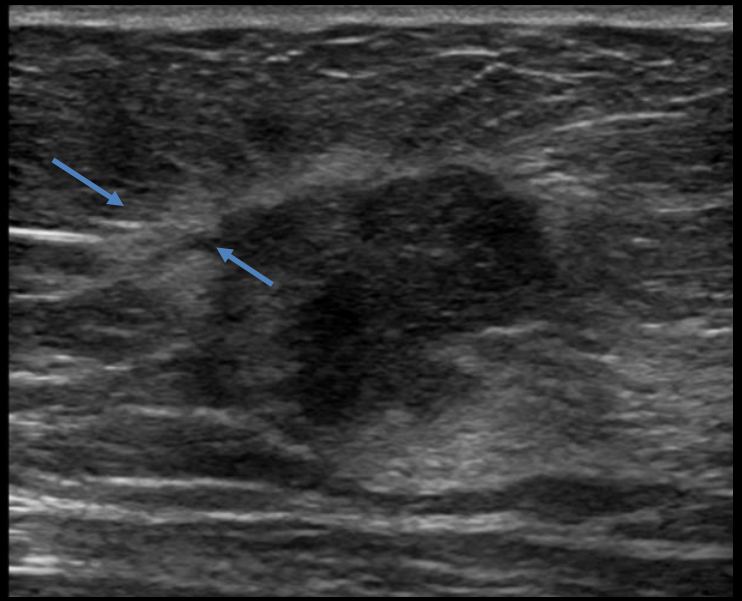

Reação desmoplásica ou edema perilesional

Deve ser incluído na mensuração = melhor correlação com medida histológica

Halo ecogênico

Halo Ecogênico

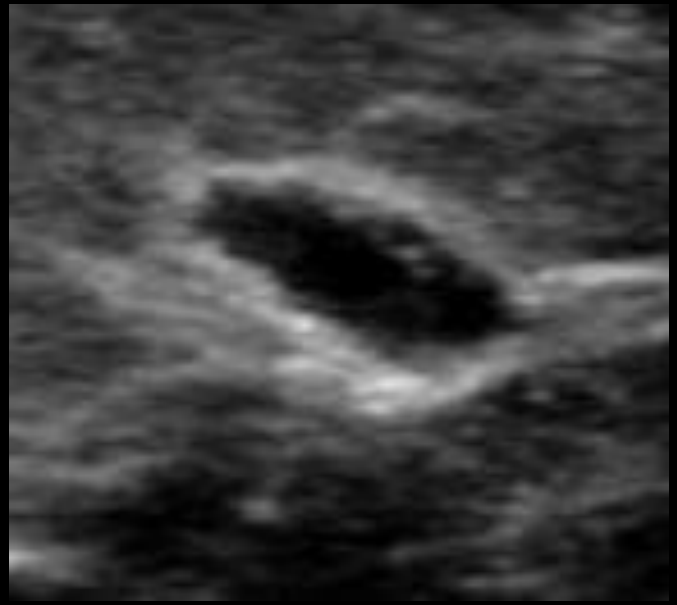

≠

Pseudocápsula

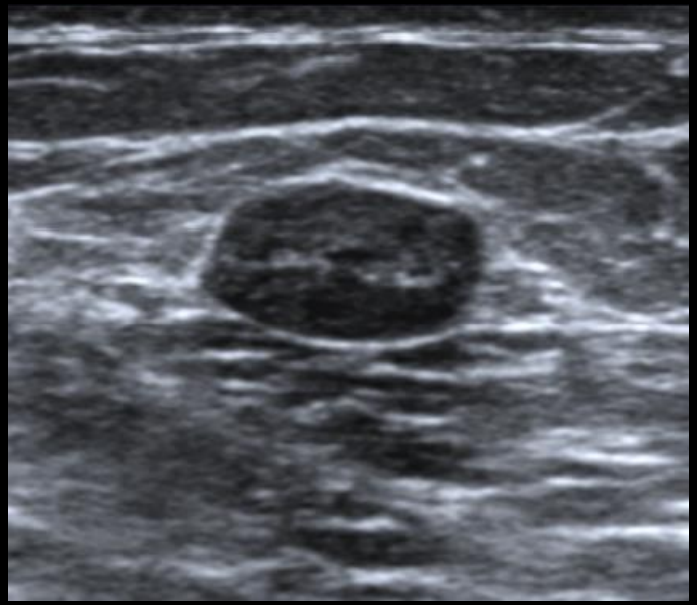

- Halo ecogênico periférico = Suspeito!
- Exceto quando tipicamente benigno = Necrose Gordurosa

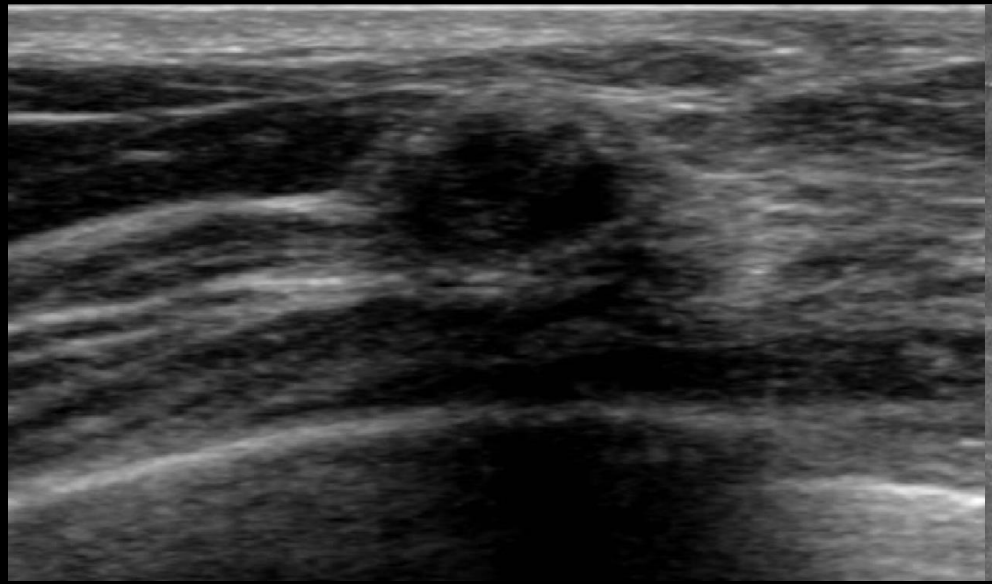

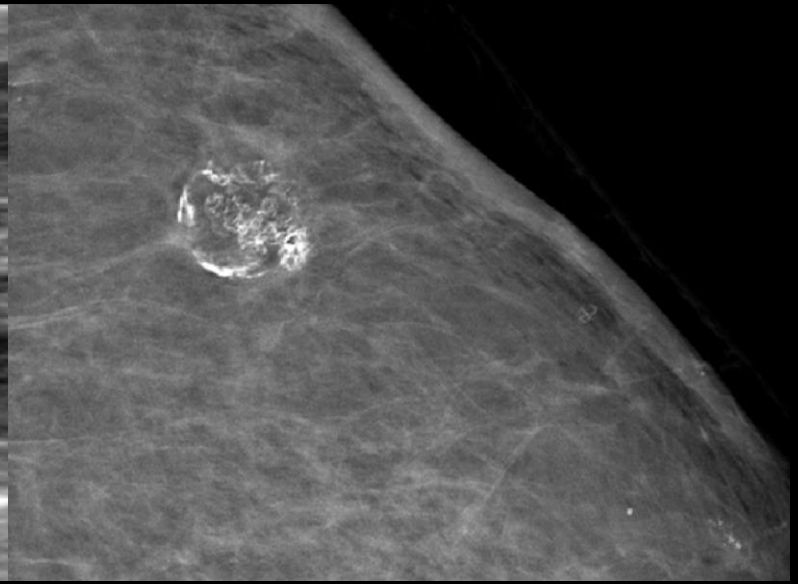

Lesões císticas mamárias

Cisto Simples

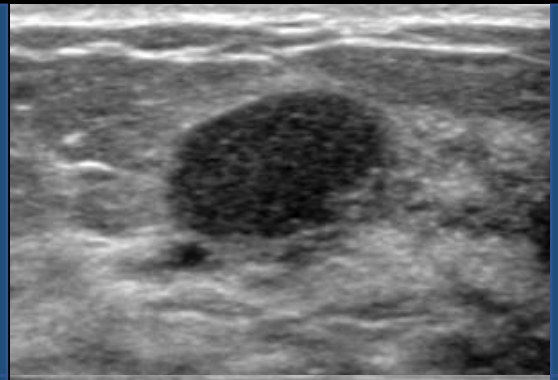

Cisto Complicado

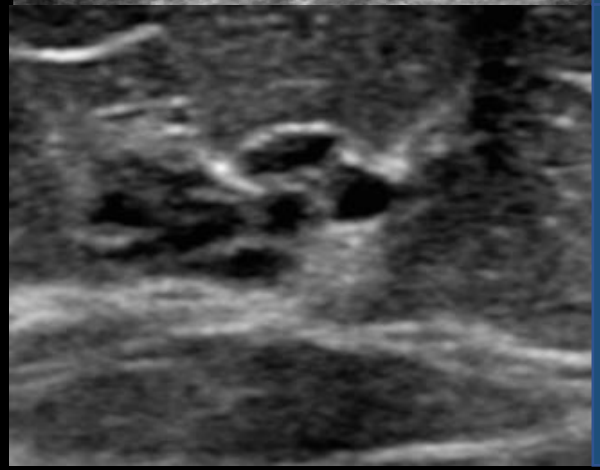

Microcistos Agrupados

Nódulo Complexo Sólido-Cístico

Léxico – Casos Especiais

CISTO SIMPLES

circunscrito, redondo ou oval, anecóico, reforço posterior,

Paredes imperceptíveis

Cisto

Simples

BI-RADS® 2

Léxico – Casos Especiais

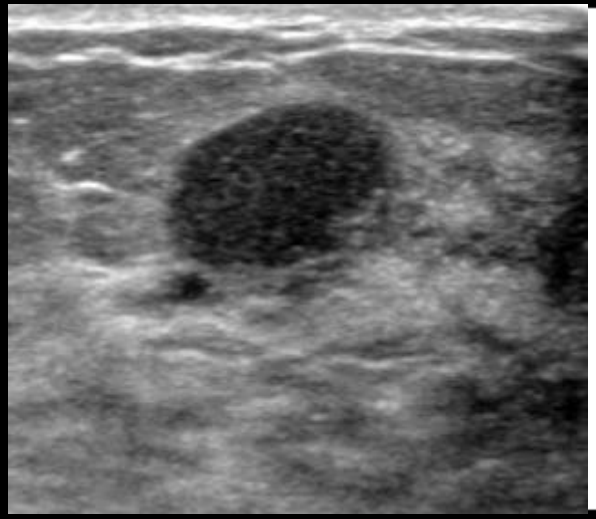

CISTO COMPLICADO/ESPESSO

cisto com debris, homogêneo, parede imperceptível

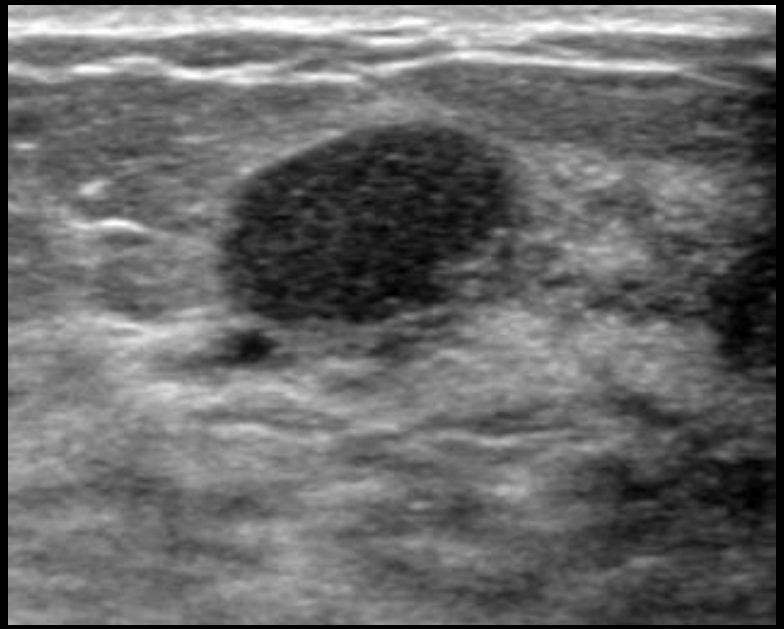

Cisto

Complicado

BI-RADS® 2/3

**confusão com nódulo sólido*

Léxico – Casos Especiais

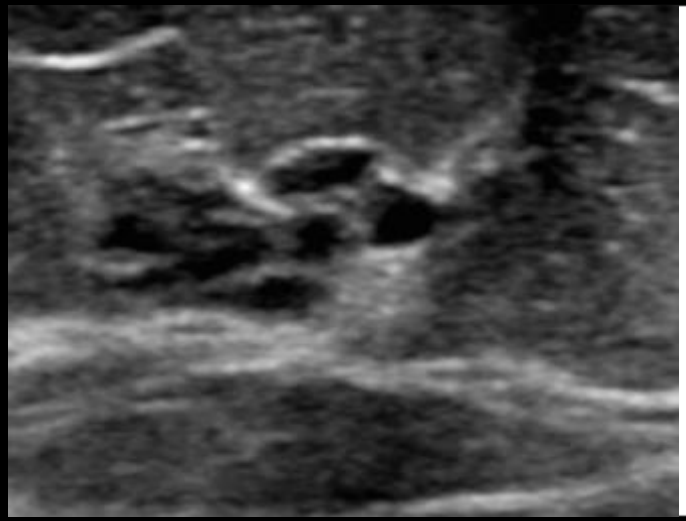

MICROCISTOS AGRUPADOS

cistos <2-3 mm, septações finas (<0,5 mm), sem componente sólido

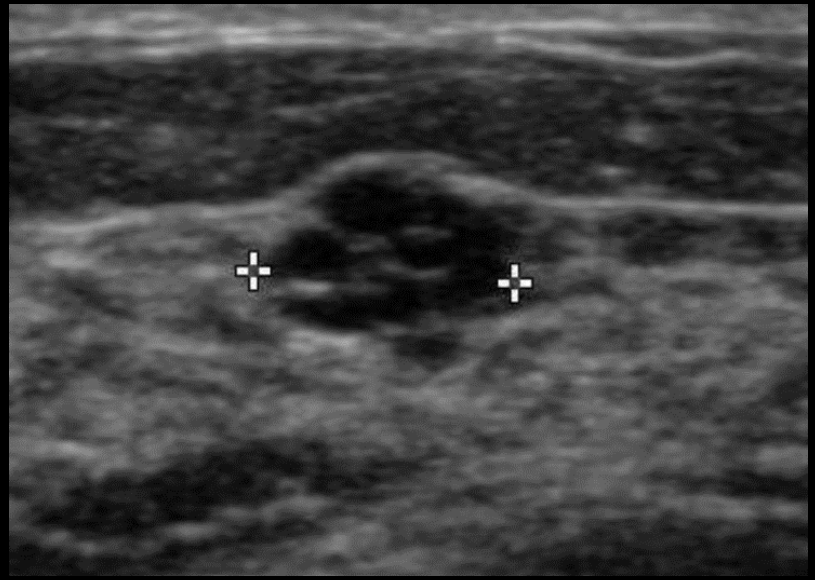

Microcistos

Agrupados

BI-RADS® 2/3*

**não enxergar porção sólida, sobretudo nos pequenos e profundos, novos na pós-menopausa*

Nódulo complexo sólido- cístico

Cisto com paredes espessas

Cisto com septações espessas

Lesão complexa predominantemente cística

Nódulo sólido com áreas císticas

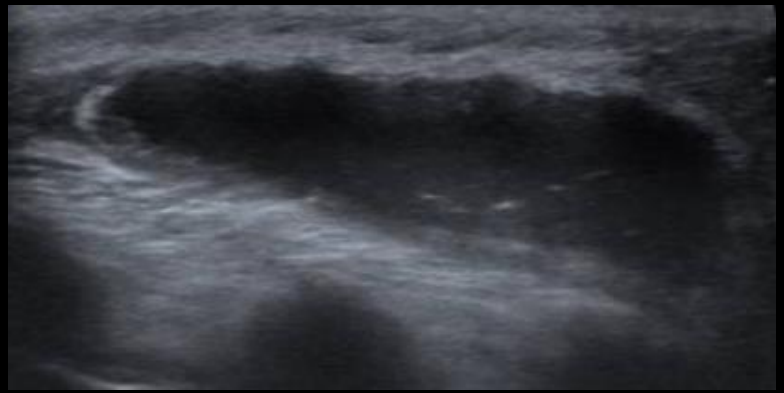

Cisto com paredes espessas

Parede ≥ 0,5 mm

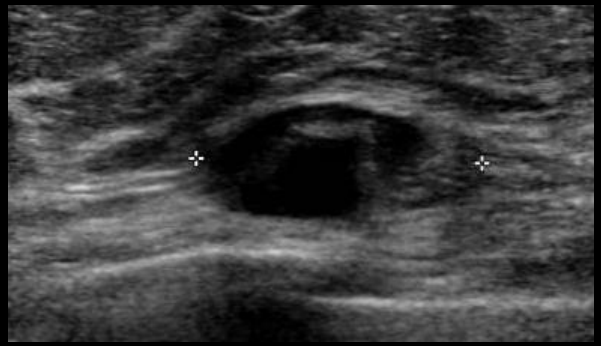

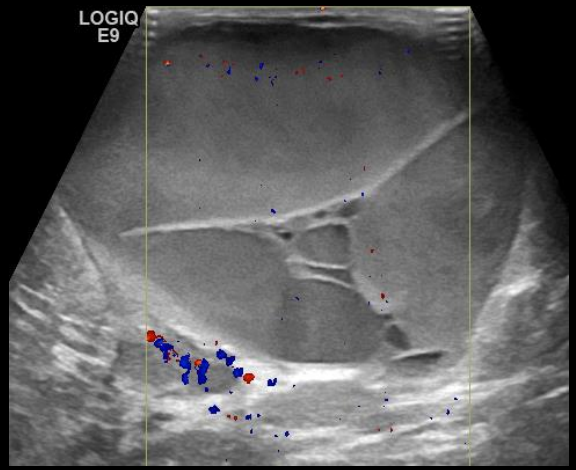

Cisto com
septações espessas

Espessura ≥ 0,5 mm

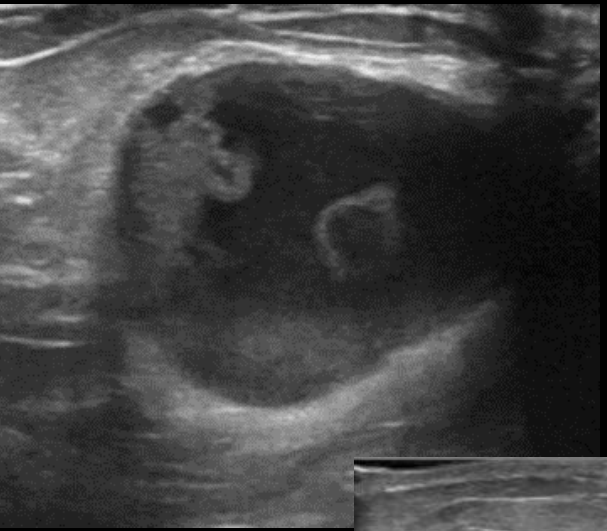

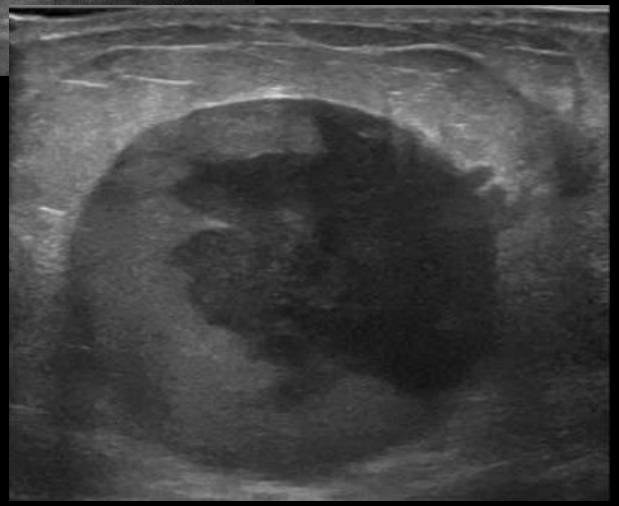

Lesão complexa predominantemente cística

Porção cística > 50%

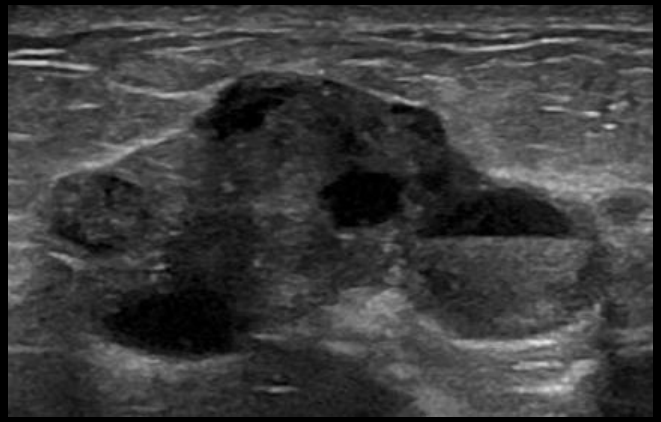

Nódulo sólido com áreas císticas

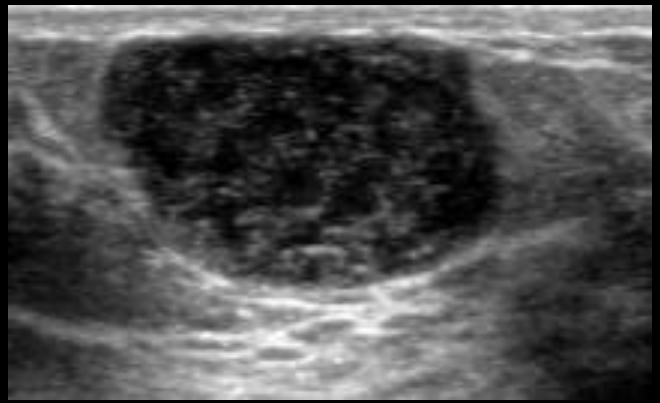

Porção sólida > 50%

TABLE 2
Correlation of Histopathologic Outcome and Sonographic Features for 150 Cystic Lesions

Finding	Simple Cyst	Complicated Cyst	Clustered Microcysts	Mass with Thick Wall and/or Thick Septations	Intracystic Mass, Mixed Cystic and Solid	Solid Mass with Eccentric Cystic Foci	Total
Benign							
Cyst	8	19 + 1*	2	3	1	1	35 (23)
FCC	0	5	6	1	3	14	29 (19)
AM	7	4	7	1	1	2	22 (15)
Abscess	1	6	0	8	2	1	18 (12)
Fibroadenoma	0	0	1	0	0	11	12 (8)
Papilloma	0	1	0	0	5	0	6 (4)
Fat necrosis	0	2	0	2	0	1	5 (3.3)
Galactocele	0	1	0	0	1	0	2 (1.3)
Periductal mastitis/cyst rupture	0	0	0	1	1	0	2 (1.3)
Lactating adenoma	0	0	0	0	0	1	1 (0.7)
Malignant							
IDC	0	0	0	6	1	2	9 (6)
IDC and DCIS	0	0	0	1	1	2	4 (2.7)
DCIS	0	0	0	0	2	1	3 (2)
ILC	0	0	0	0	0	1	1 (0.7)
IDC, DCIS, and ILC	0	0	0	0	0	1	1 (0.7)
Total	16	38 + 1*	16	23	18	38	150

30%

22%

18%

Note.—Data are the number of lesions. Data in parentheses are percentages. AM = apocrine metaplasia without other fibrocystic changes; FCC = fibrocystic changes, including fibrosis, sclerosing adenosis, and apocrine metaplasia; ILC = invasive lobular carcinoma.

* One cyst manifested multiple thin (<0.5 mm) septations.

Radiology 2003; 227:183–191

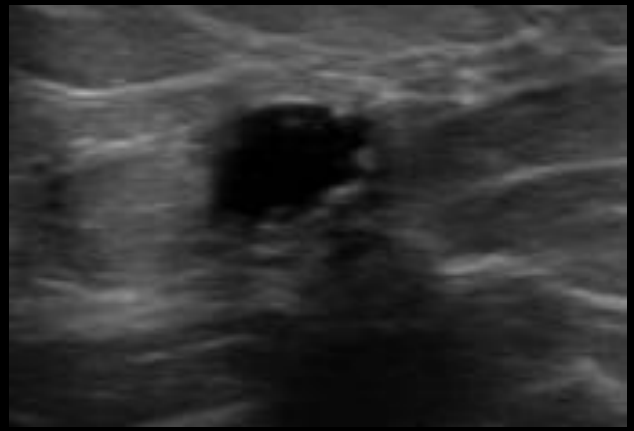

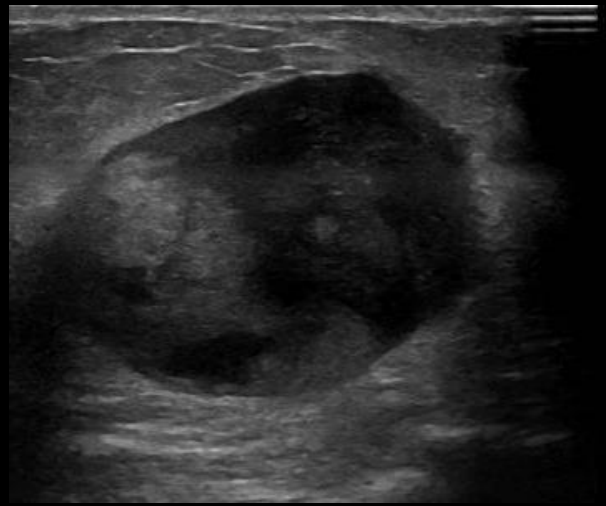

Nódulo complexo sólido-cístico

BI-RADS® 4

**afastar necrose gordurosa, hematoma e infecção*

Lesões Não Nodulares

Definição:

- Área sem configuração nodular
- Diferente do tecido fibroglandular adjacente
- Hipoecogênica, hiperecogênica (heterogênea)
- 2 planos (?)

Eur J Radiol. 2015. PMID: 25455412

Acta Radiologica 2017, Vol. 58(9) 1054–1060

Lesões Não Nodulares

Similar às calcificações/assimetria focal na mamografia ou realce não nodular na RM ou mamografia com contraste

Tem associação com estes achados

Acta Radiologica 2017, Vol. 58(9) 1054–1060

Lesões Não Nodulares

Malignas:

CDIS*;

carcinoma invasivo (ductal e lobular);

Benignas:

alteração fibrocística;

fibrose estromal;

mastite;

papiloma

Med Ultrason 2016, Vol. 18, no. 4, 446-451

Acta Radiologica 2017, Vol. 58(9) 1054–1060

Lesões Não Nodulares

- Distribuição:

  Focal – pequena (< 2 cm)

  Regional (> 2 cm)

  Linear/Segmentar

Lesões Não Nodulares

Achados associados (aumentam suspeita):

- Ductos distendidos/irregulares/extensão ductal
- Calcificações
- Distorção arquitetural
- Halo ecogênico periférico
- Sombra posterior
- Hiperfluxo ao Doppler
- Correspondência mamográfica, RM e clínica

38 anos – alteração palpável à direita

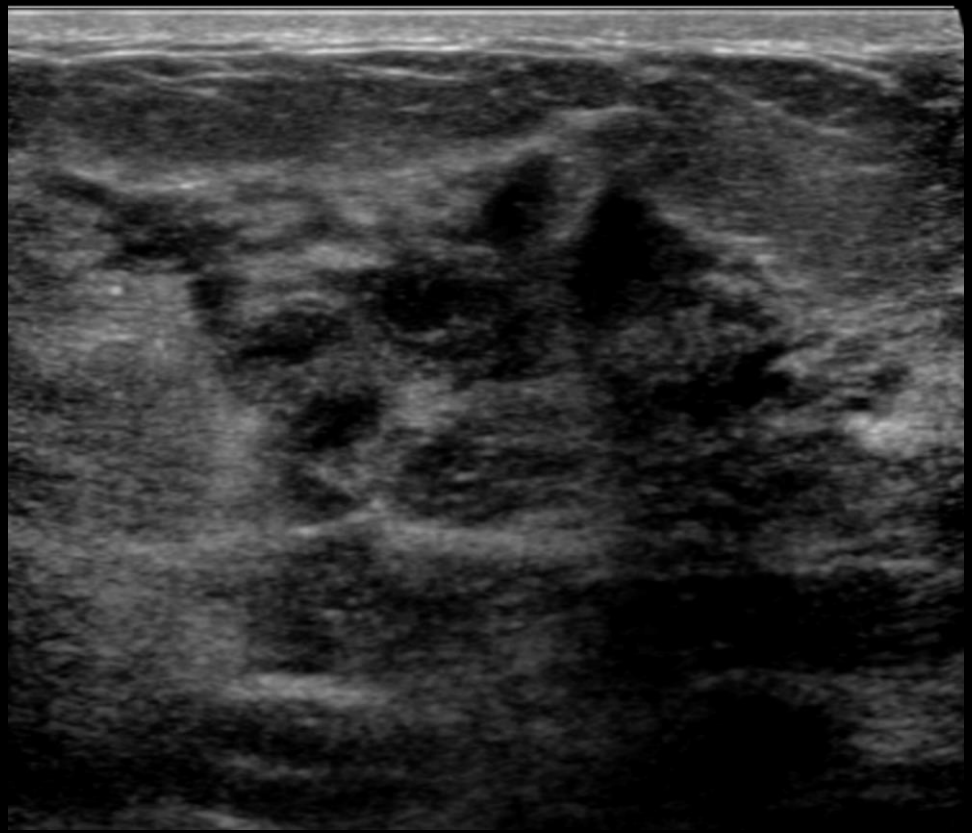

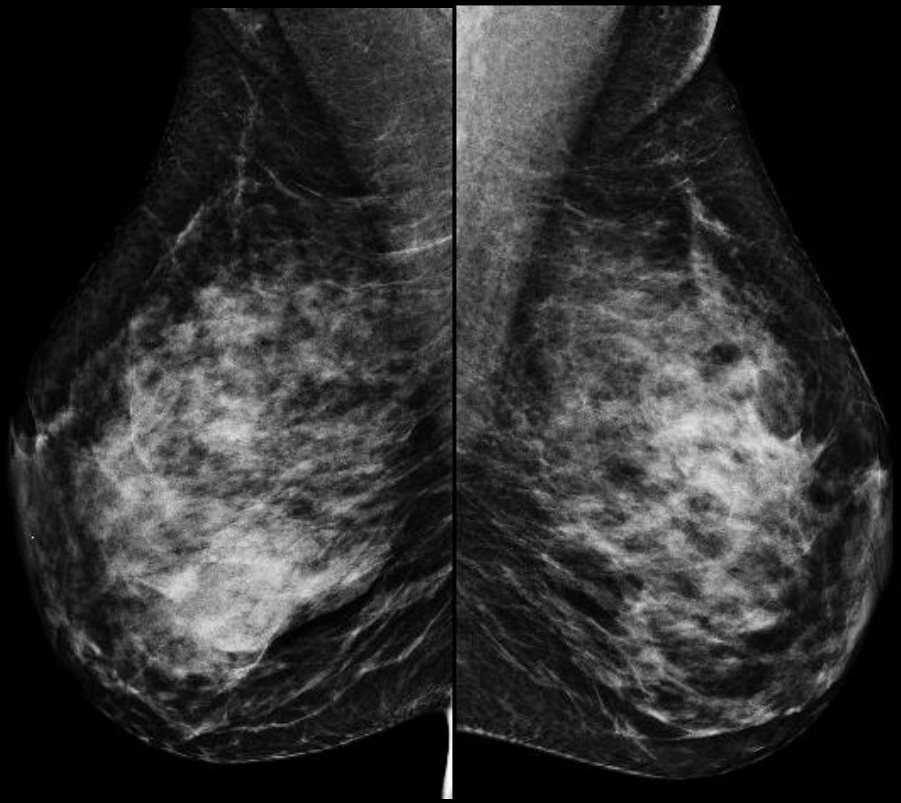

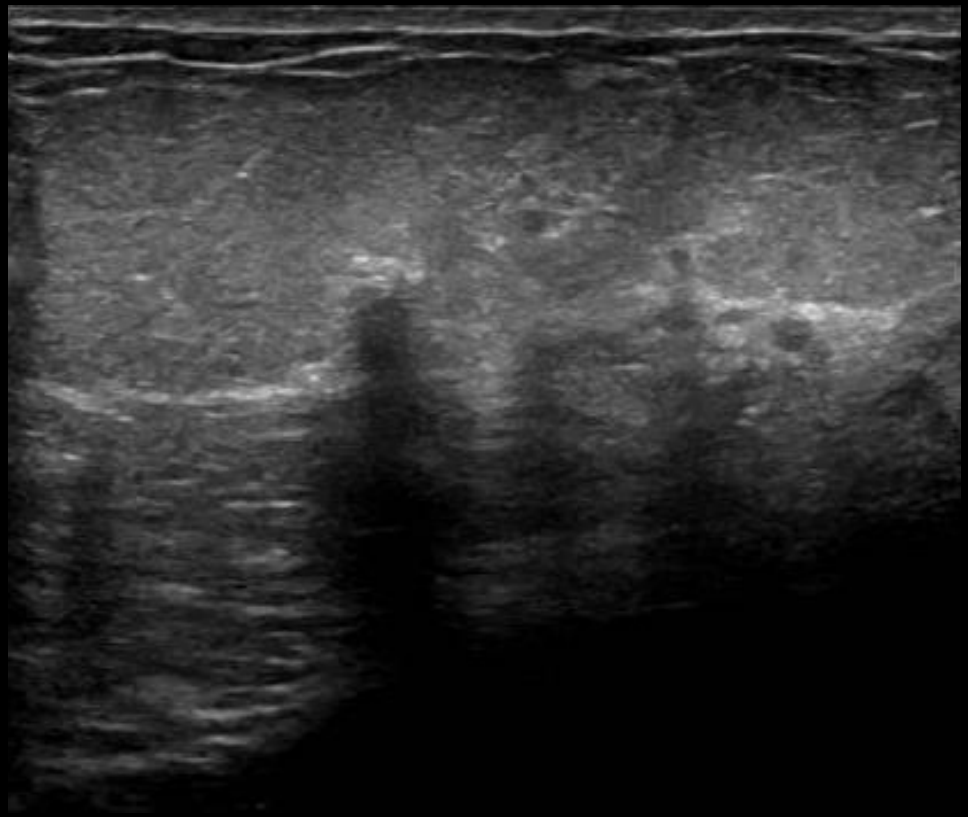

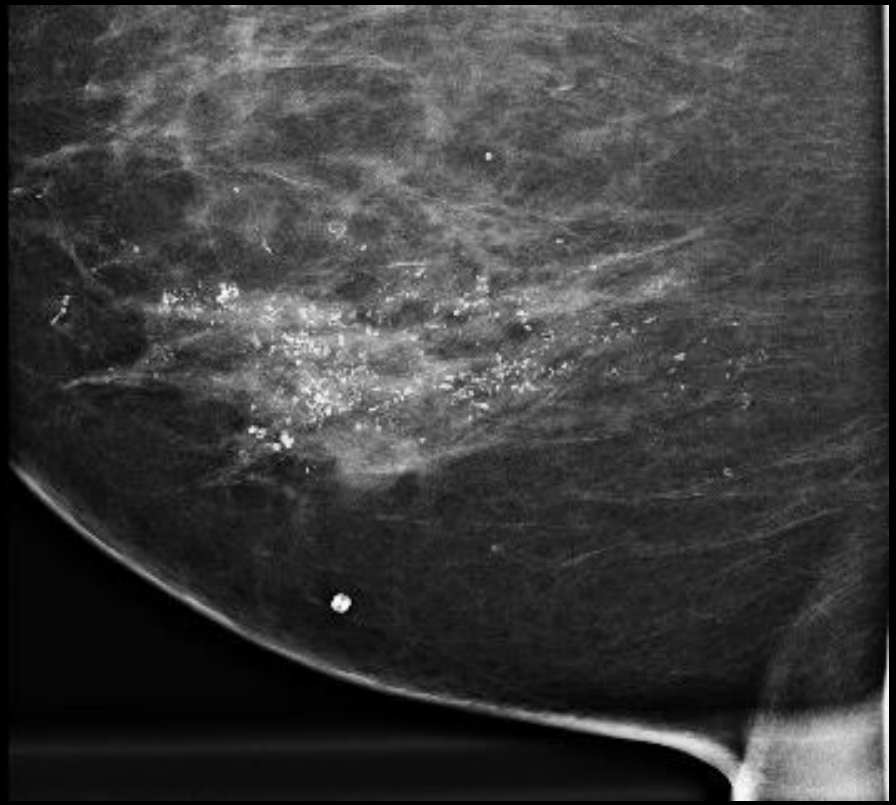

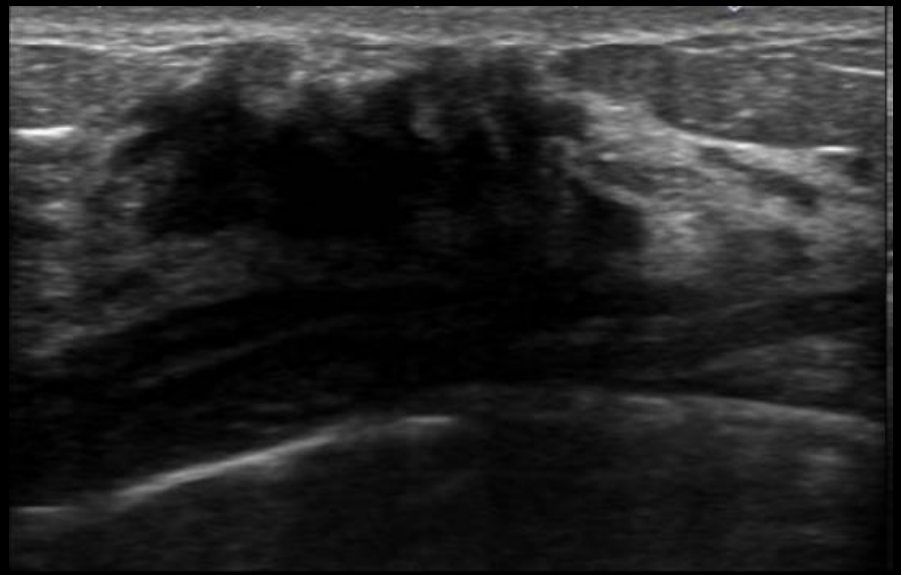

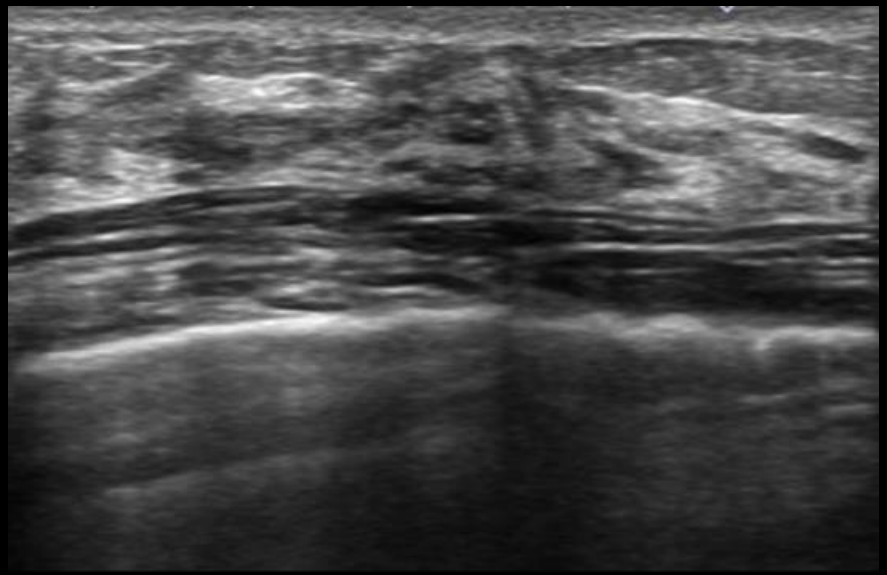

Lesões não nodulares

Atenção: usar diferentes recursos do aparelho, mudar posição do transdutor, mudar intensidade da compressão, mudar decúbito, comparar com mesma região na mama contralateral, correlação com clínica e demais exames

Linfonodo Axilar

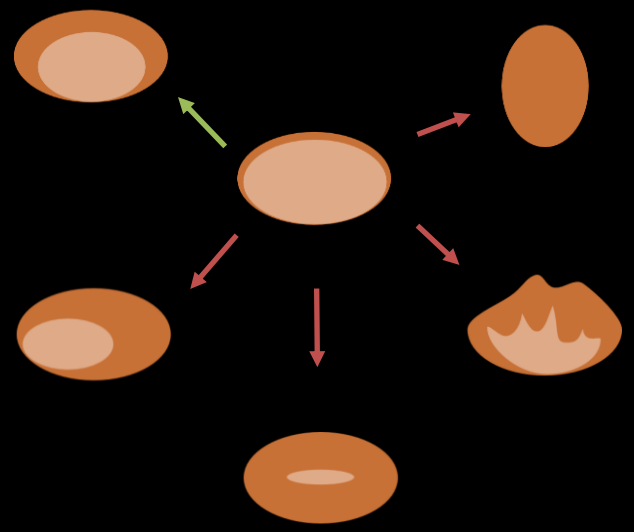

O que torna LN suspeito?

Relação cortical x hilo

Linfonodo Axilar

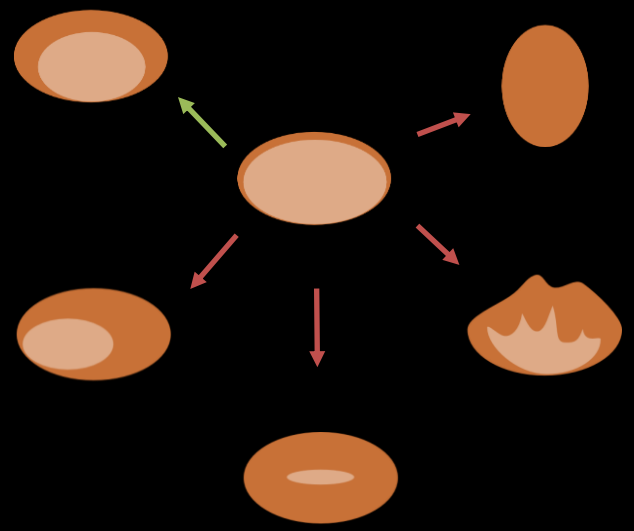

Unilateral

Bilateral

Causa Conhecida

Causa desconhecida

Dobra

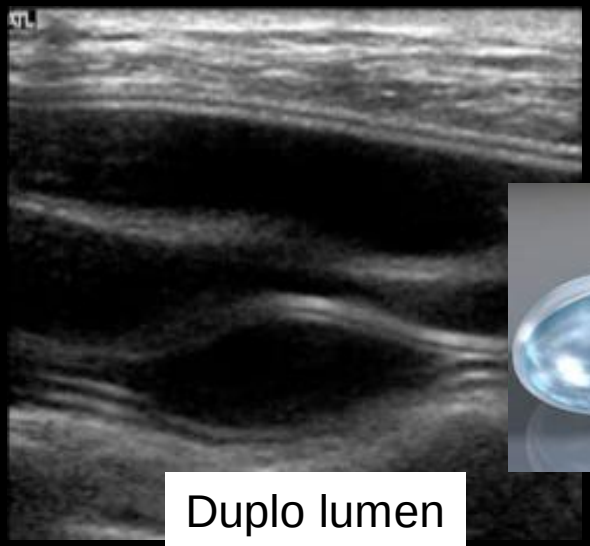

Duplo lumen

Rotação

Ruptura intra

UNIFESP
UNIVERSIDADE FEDERAL DE SÃO PAULO
1933

MAPEAMENTO DA UTILIZAÇÃO DO BREAST IMAGING REPORTING AND DATA SYSTEM (BI-RADS®) NA ULTRASSONOGRAFIA NO BRASIL

Pesquisa destinada a médicos que realizam ultrassonografia mamária

Acesse o link ou QR Code e participe deste estudo inédito

https://pt.surveymonkey.com/r/V3PZP5D

Projeto vinculado ao Programa da Pós-Graduação em Saúde Baseada em Evidências da UNIFESP

Equipe da pesquisa: Vanessa Merjane, Almir Galvão Vieira Bitencourt, César Ramos Rocha-Filho, Douglas Marcel Puricelli Perin, Alex Jones Flores Cassenote e Wagner Iared

Contato: vanessa.merjane@unifesp.br

Apoio: cbr

Financiamento: CAPES